

Close Your Eyes:
The Physician as ICU Patient
Daniel D. Shin, MD

“I like living. I have sometimes
been wildly, despairingly, acutely
miserable, racked with sorrow,
but through it all I still know
quite certainly that just to be
alive is a grand thing.”
Agatha Christie (1890-1976)

History of Present Illness
31 year-old male
-Two days of lethargy, myalgias
-Progressive weakness, call to SMG
-One day of dysuria, Cipro started
-Rounding
-Calling in to work
-Getting dressed, neck stiffness
-ER at outside hospital

Past Medical History

All: none
Meds: Cipro
PMH/PSH: fractured right wrist,
ORIF left fibula, left ear sutured,
sutures in face and head, broken nose.
SH: non-smoker, 1 drink/week, no
drugs. Married, 1 son, ID fellow.
FH: Father-type 2 diabetes, stroke
Mother-stroke

Patient Perspective of Illness

“I thought I had a routine cold, then
perhaps a UTI or prostatitis. But I
realized I had meningitis and figured I’d
be in the hospital 5-7 days.”

Hospital Course

Exam revealed mild neck stiffness
and a boggy, tender prostate
-Lumbar puncture: wbc 210 (61N
39L) rbc 50 glu 59 prot 99
-Admitted and started on amp, gent,
ceftriaxone, vancomycin
-Urine retention
-Failed SP catheter x 3 and NG
-Foley catheter, rectal tube inserted

Hospital Course

- urine, CSF, blood cx (-)
- CT pelvis shows ileus
- Rectal tube discontinued
- Afebrile, ambulating with assistance
- Day 7 transferred to Stanford
- Fevers, confusion, tried rounding
- LP: wbc 223 (N0 L57 M16 B1 rL26)
rbc 0 glu 38 prot 256
- MRI with inflammation of meninges
and spinal cord, acyclovir started

Hospital Course

- Day 9 : R leg weakness, MRI diffuse
cord swelling, cervical/thoracic
impingement, steroids
- Intubated, ICU
- Sedated and paralyzed
- Day 13: fevers, CT abd-ascites,
peritonitis, amylase increased,
meropenem

Hospital Course

- LP: wbc 142 (L77 M13 R1) glu 74
prot 92
- Day 15: Paracentesis with frank stool,
septic shock
- Laparotomy: 4 liters of stool,
perforated cecum, irrigation, R
hemicolectomy.
- Day 17: Second irrigation, ileostomy

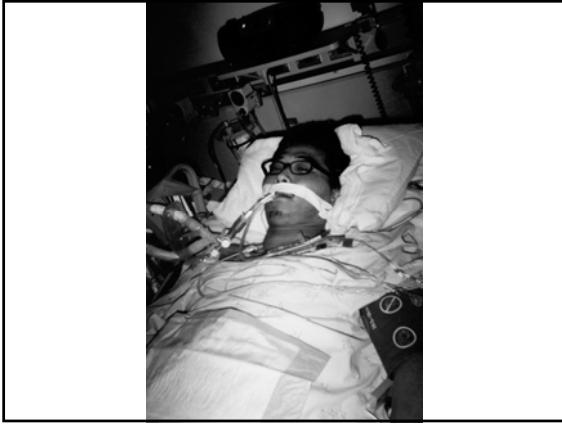Hospital Course


- Cultures with anaerobes and Candida
- Fluconazole changed to Ampho B
- Day 24: CT shows right DVT, free fluid in abdomen, heparin
- Day 26: Shock, abdomen reopened, fluid drained, chest tubes.
- Prolonged ICU course, renal failure, mechanical ventilation, antibiotics, TPN


Hospital Course


- Albumin 0.9
- IVIG given
- Day 36: IR drains into abscesses
- Transfer to hospitalist service

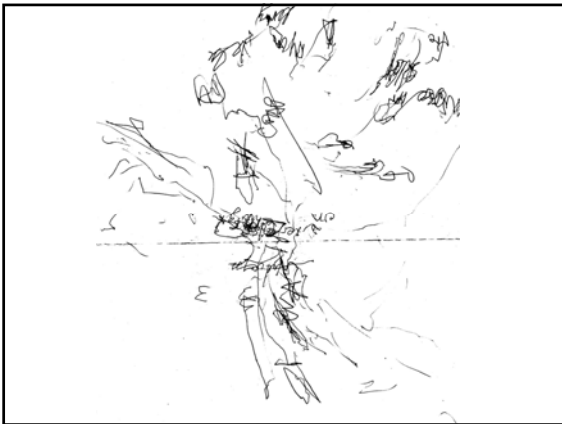


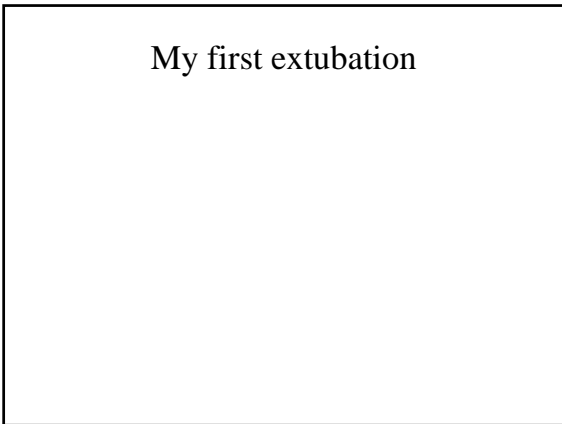
























“I don’t think the kid’s going to make it.”



Pain

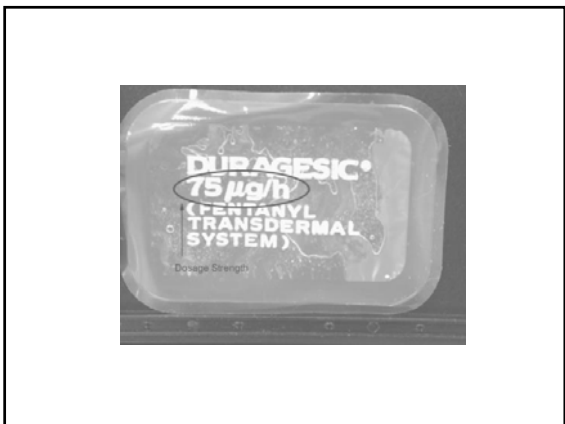- My resume
- Surgery intern
- Assessing chest pain

Disbelief

“Symptoms are never imaginary. If I say I have a headache, I am either stating a fact or telling a lie; I am not imagining I have a headache.”

F.R. Taylor, April 1941

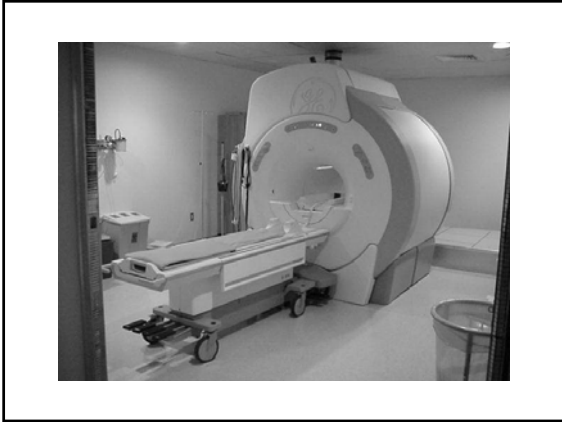“this patch has expired”



Pain

- Massage, music
- Withdrawal
- Emotional

To sedate or not sedate



Indelible images
“Pray for my husband; he is ill.”
A friend and a gesture






Our dog
Vomiting, confused
Nystagmus
Seizures
Ataxia
Hind leg weakness

Our dog
“One possibility is
granulomatous
myeloencephalitis.”

“He’s an interesting case.”

<h3>Cost</h3>	
Billed	\$782,009.99
Payment	\$509,913.57
	0.65





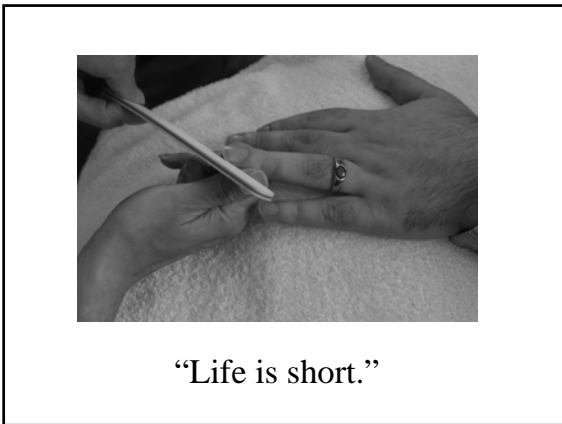











“Life is short.”

“No, Dan, life is not short, it is fragile--every moment must be cherished.”

Take home points

- 1) Patients tell the truth.
- 2) Use the gold standard for pain.
- 3) A manicure...
