

Let's Discuss Sympathetic Blocks

Janette Elliott, RN-BC, MSN, AOCN
ASPMN 19th Annual Conference
September 2009

Types of blocks

- Stellate
- Celiac plexis
- Lumbar sympathetic
- Hypogastric

Clinical considerations

- Off anticoagulation meds
 - Stop coumadin 5-7 days in advance with prescriber permission
 - Lovenox—check with prescriber
- Lumbar/Abdominal blocks
 - Able to tolerate being on abdomen ~ an hour
 - Positioning
 - Breathing
 - Comfort

Contraindications in all

- Coagulopathies
- Infections

Possible after effects

- Local discomfort
- Possible nerve damage
- Bleeding
- Infection

Stellate

- Indications
 - Acute herpes zoster & PHN
 - Acute frostbite
 - CRPS
 - Refractory angina
 - Phantom limb pain
 - Cancer pain of head, neck & upper extremities
 - Vascular insufficiency
 - Raynaud's syndrome
 - Frostbite
 - Scleroderma
 - Obliterative vascular disease
 - Some atypical vascular headaches
- Little prospective clinical data

Contraindications

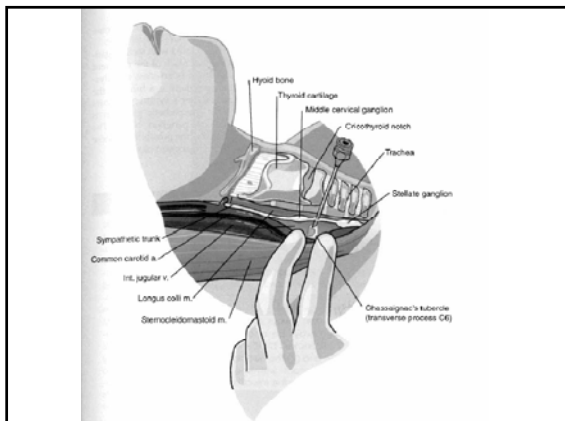
- Anticoagulants
- Contralateral pneumothorax or pneumonectomy
- Recent MI
 - Decreases cardiac sympathetic firing leading to bradycardia

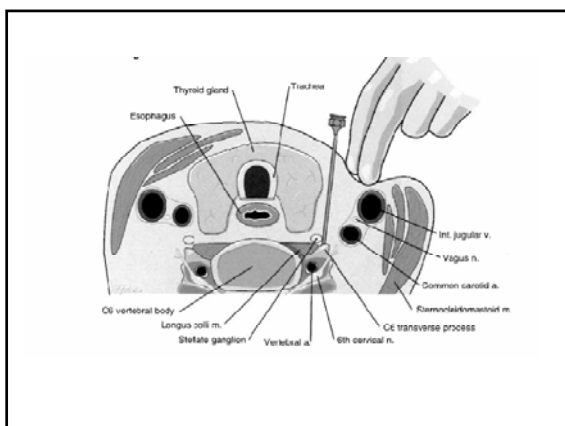
Relative contraindications

- Glaucoma
 - May worsen glaucoma
- Impaired cardiac stimulus conduction
 - Stellate can increase bradycardia

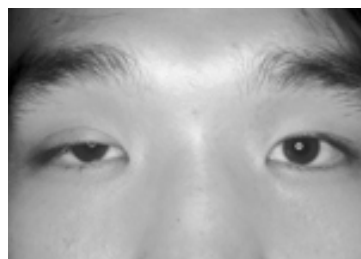How is the block done

- Anterior** or posterior approach is possible
 - Sitting or supine
 - Palpate for C6 transverse process
 - Needle straight back
 - Local anesthetic injectate
 - bupivacaine, ropivacaine
 - Phenol or alcohol for neurolytic injections
- With or without fluoroscopic guidance and contrast
- Posterior approach
 - used if infection, trauma or tumor precludes anterior approach
 - if neurolysis is desired





Horner's syndrome



- Ptosis
- Miosis

Potential side effects

- Expected
 - Horner's syndrome
 - Extremity warm to touch
- Possible
 - Hoarseness
 - Dysphagia
 - Feeling of "lump in throat"

Potential Complications

- Vascular injury
 - Injury to carotid or jugular
 - Hematoma and potential spinal cord injury
- Nerve injury
 - Injury to nerve roots
- Pulmonary injury--pneumothorax
- Spread of local anesthetic
 - Vascular
 - Epidural/intrathecal
 - "High spinal"
 - Intubate until local anesthetic wears off

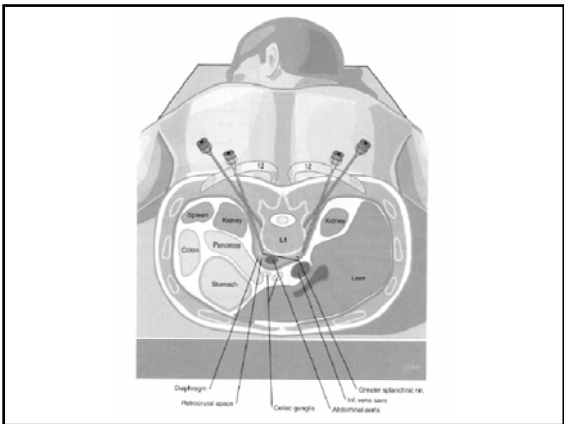
Lumbar sympathetic nerves

How these blocks are done

- Sterile prep
- Measure 2 ½-3 ½ inches from spine vertebrae—fluoro assist
 - Celiac---L1
 - Lumbar sympathetic—L2
 - Hypogastric—L5
- Insert needle to touch vertebrae
- Redirect needle so it passes by the vertebrae
- Contrast dye and fluoro to assure placement
- Infuse injectate
 - Bupivacaine, ropivacaine
 - 50% alcohol or 6% Phenol for neurolytic blocks

Celiac Plexus Block

- Indications
 - High abdominal cancers
 - Acute pancreatitis
 - Blocks may be done daily
 - Acute pain r/t hepatic artery embolization
 - Abdominal “angina” associated with visceral artery insufficiency
 - Chronic pancreatitis in select patients



Potential side effects

- Diarrhea
- Hypotension
- Increased bowel motility
 - Diarrhea ~50% of patients
 - Cramping

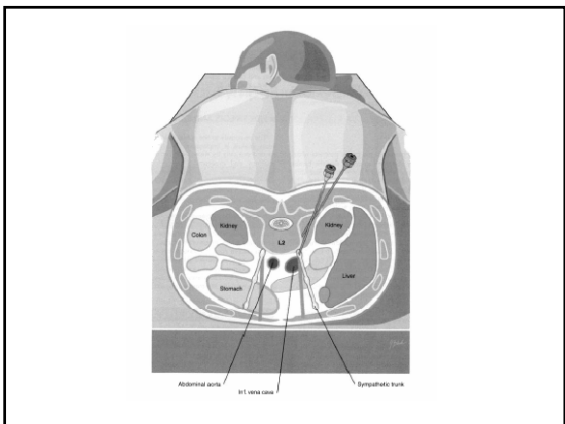
- May decrease nausea and vomiting

Potential complications

- Paralysis
- Neurologic deficits
- Discitis if too close to the disc
- Pneumothorax
- Kidney or ureter trauma if needle placed wrong
- Thoracic duct trauma if needle placed wrong

Lumbar sympathetic block

- Indications
 - CRPS
 - Circulatory insufficiency of legs
 - PVD, diabetic neuropathy, gangrene, Raynaud's, frostbite, Buerger's disease
 - Phantom pain
 - Possibly discogenic pain with pseudo-sciatic radiation
 - Hyperhidrosis
 - Pelvic malignancies--neurolytic
 - Deafferentation pain syndromes--neurolytic

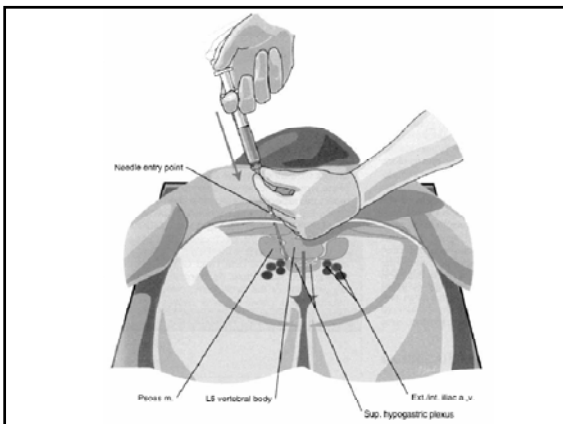


Potential side effects

- Damage to viscera
- Intraspinal injection
- Infection
- Bleeding
- Discitis

Hypogastric block

- Indications
 - Gynecologic disorders
 - Endometriosis, Adhesions, Chronic pelvic pain
 - Other lower abdominal pain problems
 - Interstitial cystitis, irritable bowel syndrome, pain after surgeries
 - Lower abdominal and pelvic cancers
 - Bladder, uterus, vagina, prostate, rectum



Monitoring during procedure

- Patent IV
- +/- sedation
- Respiratory status—constant O2 sats
- ECG monitoring
- BP q5min
- Patient comfort
- Constant “eyes on”

Monitoring after procedure

- 45-60 minutes
- Institutional monitoring for moderate sedation

Patient follow-up

- Patient specific
 - Determined by patient condition
- Clinician preference

Patient/family Education

- What it is
- How it's done
- Expected benefits
- Potential expected and unexpected side effects/complication
- When, where, how, monitoring, pain control during, post-procedure care
- Length of effect
- Can it be repeated? How often?

References

- Murata, Y. et al. (2003) Variations in the Number and Position of Human Lumbar Sympathetic Ganglia and Rami Communicantes, *Clinical Anatomy*, 102-113.
- Raj, P.P, et al (2008) *Interventional Pain Management*. Saunders.
- Waldman, Steven D. (2004) *Atlas of Interventional Pain Management*, 2nd Ed., Saunders
